

A case study evaluation of Safetac[®] dressings used for paediatric wounds

Frans Meuleneire

Abstract

Background: Wounds of paediatric patients provide a variety of unique challenges to wound care practitioners, not least the pain and sensitivity associated with the use of some of the dressings used in their management. In order to provide the best treatment options, these challenges need to be identified and overcome by using the most appropriate dressings and treatment regimens available. **Aims:** To evaluate the effect of introducing Mepilex[®] Border Lite (Mölnlycke Health Care), an absorbent foam dressing with Safetac[®] technology, in the management of paediatric wounds. **Methods:** Case report data from an observational study that was undertaken on paediatric patients with a variety of wound types are presented. **Results:** The introduction of dressings with Safetac was associated with significant reductions in pain severity compared with the levels reported with a variety of other dressings that had been previously used. Mepilex Border Lite was also found to have good handling characteristics when used on paediatric wounds. **Conclusions:** Their ability to minimise dressing-related pain and their handling characteristics makes dressings with Safetac an ideal choice for treating wounds and skin injuries of paediatric patients. **Conflict of interest:** This study was funded by Mölnlycke Health Care.

KEY WORDS

Paediatric wounds
Safetac[®] technology
Dressing-related pain
Dressing handling characteristics

The physiological course of healing in paediatric wounds is similar to that seen in adults, with the exception that children's wounds often have faster healing rates to closure (Garvin, 1990; Bale and Jones, 1996). Generally the treatments and dressings used in paediatric wound care follow the same principles that are applied to wound care for adults, except that children are potentially more sensitive and vulnerable to the effects of dressings and greater care must be taken when choosing treatment regimens to manage their wounds (Noonan et al, 2006; Baharestani,

2007). To this effect, guidelines from independent advisory groups have been effective in aiding carers to provide optimum treatment plans (Independent Advisory Group, 2004; 2005).

... children are potentially more sensitive and vulnerable to the effects of dressings and greater care must be taken when choosing treatment regimens to manage their wounds (Noonan et al, 2006; Baharestani, 2007).

Treating wounds in paediatric patients presents various challenges. For example, dressings have to be highly conformable to the small wound sizes and awkward locations of digit and limb injuries. Dressings also have to be comfortable so that the patients themselves do not interfere with them due to irritation. They also have to adhere sufficiently to the surrounding skin so that they are not displaced during bouts of energetic activity. Additionally, compared with the typical

adult patient, children may be more sensitive to the dressings and dressing change procedures they are subjected to, which may cause additional trauma and pain (Hollinworth, 2005).

It has been recognised that the most stressful (and painful) part of wound treatment for both adults and children is related to dressing changes and the removal of dressings (Hollinworth and Collier, 2000). As a result of collaborations and discussions between experts in the field of wound care, guidelines have been presented that outline best practice and the criteria for dressings that should be considered in order to minimise trauma and pain during dressing-related procedures, for example, moist wound healing, fluid handling capacity, atraumatic removal and low allergy potential (European Wound Management Association [EWMA], 2002; World Union of Wound Healing Societies [WUWHS], 2004; 2007).

Safetac[®], an atraumatic adhesive technology, is based on 'soft' silicone, a material that adheres readily to intact dry skin but does not stick to the surface of a moist wound or

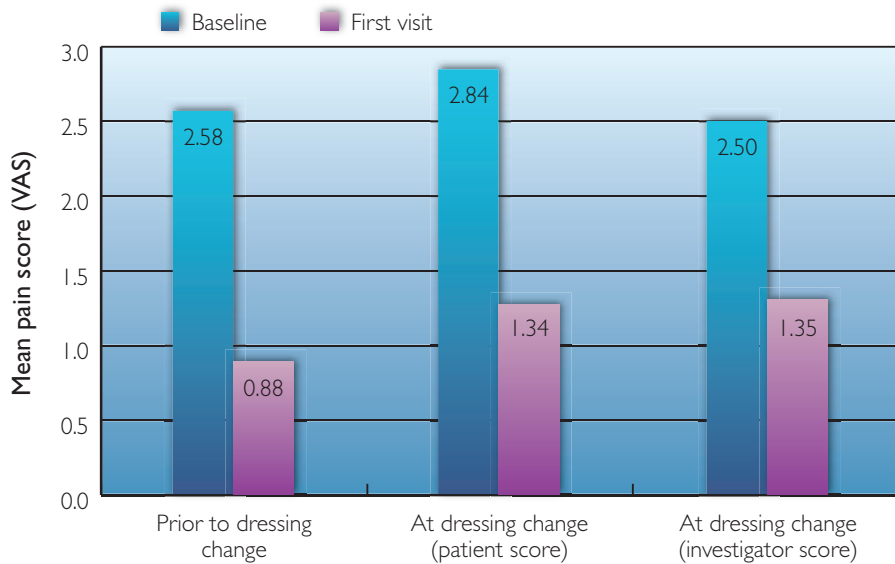


Figure 1. Mean pain severity scores recorded (baseline and first visit) before and during dressing change with Mepilex Border Lite (patients' and investigator's evaluations).

cause damage on removal. The nature of the bond that forms between dressings which incorporate Safetac technology and the skin surface allows the dressings to be removed without causing trauma to the peri-wound skin (Dykes et al, 2001; Zillmer et al, 2006; Dykes, 2007; Waring et al, 2008), or damaging delicate new tissues at the wound margin (White, 2005). In addition, dressing-related pain is minimised as a consequence of their atraumatic properties (Dykes and Heggie, 2003; White, 2008).

Dressings with Safetac have been shown to be highly effective and extremely well-tolerated in a number of clinical evaluations involving paediatric wounds, for example, in the treatment of burns (Bugmann et al, 1998; Gotschall et al, 1998; Greenwood et al, 2000; Williams et al, 2001), surgical wounds (Terrill and Varughese, 2000), traumatic wounds (O'Donovan et al, 1999), and epidermolysis bullosa (Lapioli-Zufelt and Morris, 1998; Spitz and Rosslein, 1998; Denyer, 2000; Hall, 2004; Denyer, 2006). These dressings have also been demonstrated to be beneficial in the fixation of skin grafts (Vloemans and Kreis, 1994; Platt et al, 1996; Chavez, 2004), the management of neonatal peristomal wounds (Kaufman, 2008), the healing of a sacral haemangioma that presented in a four-month-old infant (Stephen-

Haynes, 2004), and in the prevention of trauma to the nasal septum and peri-nasal tissue during the course of continuous positive air pressure therapy when treating premature babies (Smith, 2006).

In addition to the above studies, a multi-centre, observational study (Morris et al, 2009) was recently undertaken to assess dressings with Safetac in the management of different types of paediatric wounds and skin injuries, such as traumatic wounds (cuts, scrapes, skin tears, abrasions, finger/toe injuries, and blisters), surgical wounds, and contact dermatitis. The primary objective of the study was to compare the pain severity levels at baseline (after a variety of different dressings had been used to treat the wound) to the pain levels after switching the patients to treatment with Mepilex® Border Lite (Mölnlycke Health Care, Gothenburg, Sweden), an absorbent foam dressing with Safetac. Secondary objectives included the evaluation of the application and handling of the dressings. Each patient was followed for six weeks or until the wound/skin injury had healed, or whichever occurred earlier.

The results of this study showed that dressings with Safetac were associated with significantly less pain at dressing change than a variety of other

conventional dressings. The introduction of dressings with Safetac was associated with a statistically significant reduction in pain severity ($p \leq 0.003$), compared with the levels reported at baseline (Figure 1). In addition, both the patients and the investigator showed a preference for dressings with Safetac.

Four of the patients included in the study are presented here as more detailed case reports. As part of the original research team, the author wishes to demonstrate how dressings with Safetac can overcome the clinical challenges (dressing-related pain, awkward location and small size of wounds) faced by clinicians when managing the wounds of paediatric patients in a practical clinical environment.

Case report 1

A 10-year-old male patient with no underlying diseases or concerns about his medical history presented with a necrotising, traumatic injury to the tip of the fifth digit on his right hand. He subsequently had an amputation. The resulting wound had proved difficult to dress with conventional dressings due to its small size and location. At the beginning of the study, the wound was three days old and in good condition (90% viable tissue present) (Figure 2). Nevertheless, the patient experienced significant pain both before dressing change (VAS score 5 on a scale of 0–10) and at dressing removal (VAS score 6). After introducing Mepilex Border Lite (Figure 3), both VAS scores dropped immediately to 3 and had

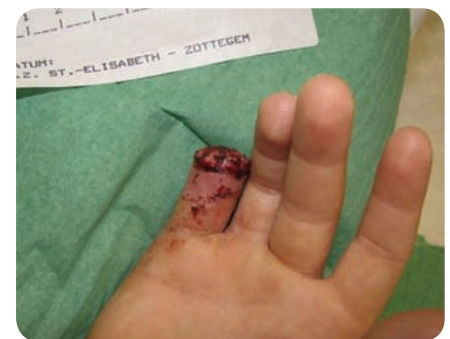

Figure 2. Case report 1: a traumatic wound to fifth digit (post-amputation) at first dressing change, illustrating the clinical challenge relating to the awkward location and small size of the wound.

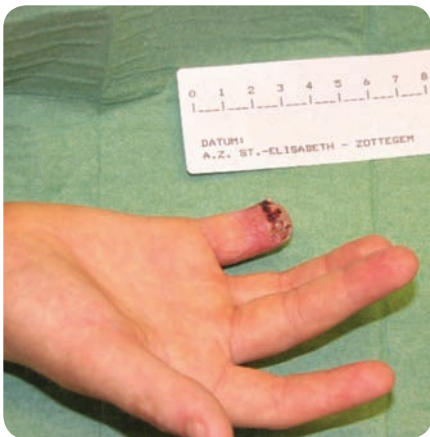

Figure 3. Case report 1: at third dressing change, seven days later. Good healing progression and significantly reduced inflammation can be observed.

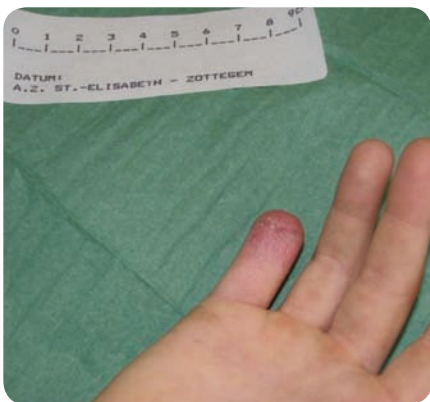

Figure 4. Case report 1: at final dressing change after 25 days of treatment. The wound had completely healed, without complications.

dropped to 1 by the fourth week of treatment when the wound had completely healed (Figure 4). Both the patient and his parents were satisfied with the performance of the dressing and rated it highly (8 on a scale of 1–10).

Case report 2

A 13-year-old male patient presented with a three-day-old traumatic burn wound to the lower right leg above the heel caused by contact with a hot motorcycle engine. The boy was active and the position of the wound on the heel where movement occurred made retention of the dressing difficult (Figure 5). At presentation, the wound was very painful both before and during dressing changes (VAS score 6). However, the pain severity dropped significantly when Mepilex Border Lite was introduced (VAS scores of 3 and 2 for before and

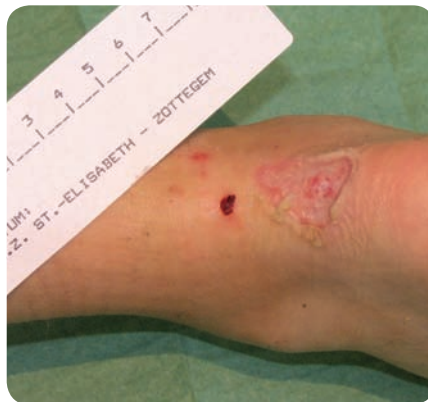

Figure 5. Case report 2: a traumatic burn wound in an awkward position above the heel at first dressing change. The position of the wound made it very painful for the patient to walk.

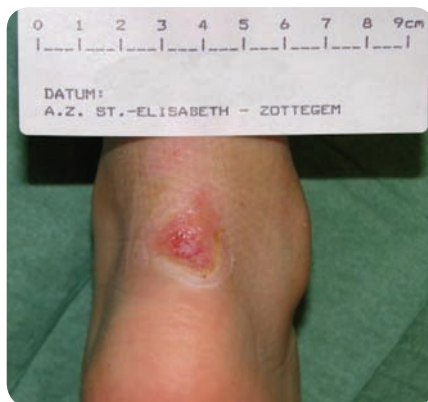

Figure 6. Case report 2: at eighth dressing change. Good re-epithelialisation with minimal inflammation observed. Wound progressed to complete healing.

during dressing changes, respectively). Within a few days, the wound was being treated at home and the patient was able to wear shoes comfortably and resume normal activities. The wound healed completely with about three weeks of treatment with Mepilex Border Lite (Figure 6).

Case report 3

A one-year-old male patient presented with a traumatic injury which resulted in amputation of the fifth digit and a damaged fourth digit on his right hand. The wound was four days old at presentation to the clinic. It was very painful before dressing change (VAS score 5) and during dressing removal (VAS score 7). The size and location of the wound, plus the disposition of the very young patient who was anxious during the procedure, made it difficult to change and re-dress the wound

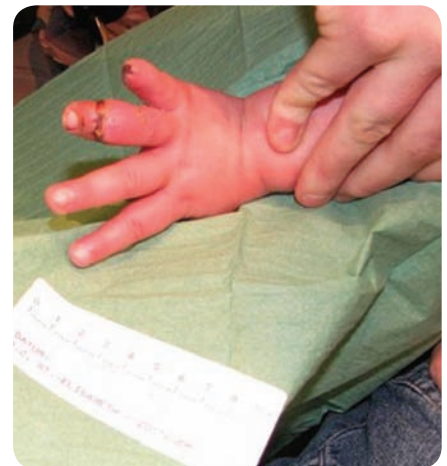

Figure 7. Case report 3: traumatic digit injuries (one resulting from amputation) at first dressing change.

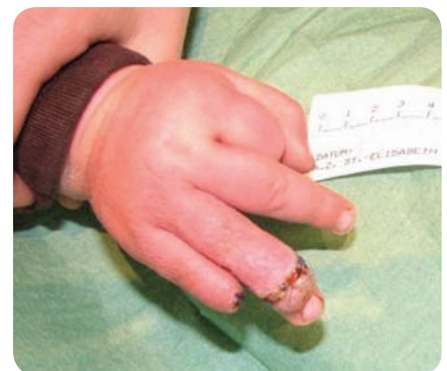

Figure 8. Case report 3: at third dressing change, after five weeks of treatment. Good healing progression observed, ultimately allowing successful reconstructive surgery to take place

(Figure 7). The highly conformable and flexible nature of Mepilex Border Lite helped to overcome these problems. However, the pain suffered by the patient as recorded by the investigator showed a gradual decline during treatment with Mepilex Border Lite. In terms of patient comfort, conformability, handling and ease of removal, the investigator rated the dressings as good. After five weeks of treatment, good healing progression was observed (Figure 8), which ultimately allowed the patient to have successful reconstructive surgery.

Case report 4

A 12-year-old girl with no underlying diseases or concerns about her medical history presented with a series of wounds to the plantar regions of both feet as a result of surgical removal of verrucae (Figure 9). She was

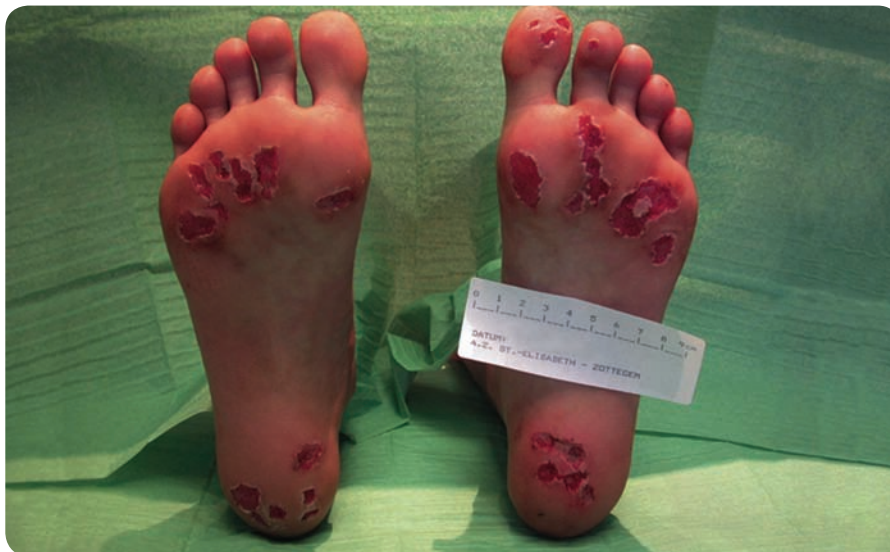

Figure 9. Case study 4: post-surgical wounds on the plantar surfaces of the feet, at first dressing change.



Figure 10. Case report 4: Mepilex Border Lite dressings in situ enabled patient to return to full mobility and complete wound healing.

experiencing significant discomfort on walking as a result of these wounds. Mepilex Border Lite was applied to the soles of the feet (Figure 10), resulting in rapid resolution of discomfort, a return to full mobility and complete healing. The dressing conformed well to the surfaces of the feet and remained securely in place between dressing changes.

Discussion

Paediatric patients require knowledgeable and sensitive management and present unique challenges in all areas of healthcare, which is certainly the case when it comes to wound management. Compared with adults, paediatric patients tend to present with wounds on a much smaller scale, requiring smaller, thinner, more flexible and

conformable dressings. On the other hand, these dressings may be subject to more rigorous physical challenges, for example, staying in place on an energetic child who may also be inquisitive and want to displace the dressing. Dressings used in the paediatric setting need to be able to address these issues in addition to the 'normal' requirements, such as protection from further trauma, prevention of ingress of micro-organisms and fluid absorption (if required).

Morris et al (2009) evaluated the use of Mepilex Border Lite in a paediatric population in which all of these issues were considered. The overall results have shown that the dressing overcame the day-to-day challenges when applied to paediatric

Key Points

- ▶▶ Paediatric wounds present unique and difficult clinical challenges to the care giver.
- ▶▶ Paediatric patients may be more sensitive to pain and trauma induced by adhesion of conventional dressings.
- ▶▶ Dressings with Safetac technology minimise pain associated with dressing changes.
- ▶▶ Mepilex Border Lite has been shown to be successful in overcoming the physical challenges associated with dressing wounds in paediatric patients.

wounds and continued to do so over the period it was in place. The primary aim of the study was to evaluate the effect of Mepilex Border Lite on dressing-related pain. Pain and the perception of pain is a major issue with paediatric patients (as it is with adults), but, in the majority of cases, logical reasoning with the patient relating to why dressings must be used and may be painful is not an option. Therefore, careful selection of dressings and treatment regimens to reduce patient suffering and maintain compliance is paramount. The key finding of Morris et al's (2009) study was that the introduction of Mepilex Border Lite was associated with a significant reduction in dressing-related pain compared with the pain levels reported with conventional dressings. For the paediatric patient (and their parents) this is of profound importance. The study also demonstrated the excellent conformability of the dressing, its ease of use and removal, and the high level of patient comfort associated with its use. The case reports presented in this article further support these observations, demonstrating the suitability of Mepilex Border Lite for the

awkward location and relatively small size of many paediatric wounds.

Conclusion

The clinical challenges presented by the paediatric patient in wound care require careful, considerate and experienced evaluation by professional healthcare workers. Dressings must be carefully chosen to overcome these challenges. The data presented in Morris et al's (2009) study shows the significant benefits of Mepilex Border Lite over a variety of conventional dressings in the treatment of paediatric wounds, particularly in relation to the reduction in pain experienced by the patients when switched to the dressing which utilises Safetac technology. This has been reiterated in the case reports presented here which show that these atraumatic dressings minimise pain at dressing changes and are ideally suited to overcoming many of the challenges faced by clinicians in managing paediatric wounds. **WUK**

References

- Baharestani MM (2007) An overview of neonatal and pediatric wound care knowledge and considerations. *Ostomy Wound Manage* 53(6): 34–40
- Bale S, Jones V (1996) Caring for children with wounds. *J Wound Care* 5(4): 177–80
- Bugmann P, Taylor S, Gyger D (1998) A silicone-coated nylon dressing reduces healing time in burned paediatric patients in comparison with standard sulfadiazine treatment: a prospective randomized trial. *Burns* 24(7): 609–12
- Chavez B (2004) Making the case for using a silicone dressing in burn wound management. *Ostomy Wound Manage* 50(6): 11–2
- Denyer J (2000) Management of severe blistering disorders. *Semin Neonatol* 5(4): 321–4
- Denyer J (2006) The use of atraumatic wound dressings in epidermolysis bullosa. Poster presentation at the European Wound Management Association conference, Prague, Czech Republic
- Dykes PJ (2007) The effect of adhesive dressing edges on cutaneous irritancy and barrier function. *J Wound Care* 16(3): 97–100
- Dykes PJ, Heggie R (2003) The link between the peel force of adhesive dressings and subjective discomfort in volunteer subjects. *J Wound Care* 12(7): 260–2
- Dykes PJ, Heggie R, Hill SA (2001) Effects of adhesive dressings on the stratum corneum of skin. *J Wound Care* 10(2): 7–10
- European Wound Management Association (2002) Position Document: *Pain at Wound Dressing Changes*. Medical Education Partnership, London
- Garvin G (1990) Wound healing in pediatrics. *Nurs Clin North Am* 25(1): 181–92
- Gotschall CS, Morrison MI, Eichelberger MR (1998) Prospective, randomized study of the efficacy of Mepitel on children with partial-thickness scalds. *J Burn Care Rehabil* 19(4): 279–83
- Greenwood JE, Dunn KW, Davenport PJ (2000) Experience with severe extensive skin blistering disease in a paediatric burns unit. *Burns* 26(1): 82–7
- Hall S (2004) Life, epidermolysis bullosa and chasing tornadoes. *J Wound Care* 13(10): 405–6
- Hollinworth H (2005) *Pain at wound dressing-related procedures: a template for assessment*. World Wide Wounds. Available online at: www.worldwidewounds.com/2005/august/Hollinworth/Framework-Assessing-Pain-Wound-Dressing-Related.html (last accessed 10 March, 2009)
- Hollinworth H, Collier M (2000) Nurses' views about pain and trauma at dressing changes: results of a national survey. *J Wound Care* 9(8): 369–73
- Independent Advisory Group (2004) Issues in Paediatric Wound Care. Minimising Trauma and Pain. Available online at: www.molnlycke.net/Files/Wound_Care/Issues%20in%20Paediatric%20Wound%20Care%20Minimising%20Trauma%20and%20Pain.pdf (last accessed 10 March, 2009)
- Independent Advisory Group (2005) Issues in Neonatal Wound Care. Minimising Trauma and Pain. Available online at: www.molnlycke.net/Files/Wound_Care/Issues%20in%20Neonatal.pdf (last accessed 10 March, 2009)
- Kaufman LM (2008) When small stomas are a big deal: the use of a soft silicone pouching system on the neonatal ostomate complicated by a peristomal wound. Poster presentation at the 40th Annual Conference of the Wound Ostomy and Continence Nurses Society, Orlando, Florida, United States of America
- Lapioli-Zufelt A, Morris EJ (1998) Skin and wound care management for a child with epidermolysis bullosa. *J Wound Ostomy Continence Nurs* 25(6): 314–6
- Morris C, Emsley P, Marland E, Meuleneire F, White R (2009) Use of wound dressings with soft silicone adhesive technology. *Paediatr Nurs* 21(3): 38–43
- Noonan C, Quigley S, Curley MA (2006) Skin integrity in hospitalized infants and children: a prevalence survey. *J Pediatr Nurs* 21(6): 445–53
- O'Donovan DA, Mehdi SY, Eadie PA (1999) The role of Mepitel silicone net dressings in the management of fingertip injuries in children. *J Hand Surg (Br)* 24(6): 727–30
- Platt AJ, Phipps A, Judkins KA (1996) A comparative study of silicone net dressing and paraffin gauze dressing in skin-grafted sites. *Burns* 22(7): 543–5
- Smith ZK (2006) Addressing the pain: adapting a soft silicone dressing to enhance infant outcomes. *Ostomy Wound Manage* 52(4): 30–2
- Spitz C, Rosslein R (1998) [Epidermolysis bullosa hereditaria dystrophica mutilans Hallopeau-Siemens; a complex problem]. *Handchir Mikrochir Plast Chir* 30(2): 71–81
- Stephen-Haynes J (2004) Vascular birthmarks: a case study of an infant with haemangioma. *Br J Nurs* 13(2): 87–93
- Terrill PJ, Varughese G (2000) A comparison of three primary non-adherent dressings applied to hand surgery wounds. *J Wound Care* 9(8): 359–63
- Vloemans AF, Kreis RW (1994) Fixation of skin grafts with a new silicone rubber dressing (Mepitel). *Scand J Plast Reconstr Surg Hand Surg* 28(1): 75–6
- Waring M, Rippon M, Bielfeldt S, Brandt M (2008) Cell attachment to adhesive dressings: qualitative and quantitative analysis. *Wounds UK* 4(3): 35–47
- White R (2005) Evidence for atraumatic soft silicone wound dressing use. *Wounds UK* 1(3): 104–9
- White R (2008) A multinational survey of the assessment of pain when removing dressings. *Wounds UK* 4(1): 14–22
- Williams G, Withey S, Walker CC (2001) Longstanding pigmentary changes in paediatric scalds dressed with a nonadherent siliconised dressing. *Burns* 27(2): 200–2
- World Union of Wound Healing Societies (2004) Principles of best practice: Minimising pain at wound dressing-related procedures. A consensus document. Medical Education Partnership, London
- World Union of Wound Healing Societies (2007) Principles of best practice: Minimising pain at wound dressing-related procedures: 'Implementation of pain relieving strategies'. Evidence informed practice. WoundPedia Inc, Toronto
- Zillmer R, Agren MS, Gottrup F, Karlsmark T (2006) Biophysical effects of repetitive removal of adhesive dressings on peri-ulcer skin. *J Wound Care* 15(5): 187–91